

Urethral Caruncle Masquerading a Primary Amelanotic Melanoma, the Risk of a Poor Prognosis due to Misdiagnosis

Paola Algeri; M.D.¹, Jessica Munné-Collado; M.D.², Maurizio Algeri; M.D.³

1 Department of Obstetrics and Gynaecology, Bolognini Hospital, ASST Bergamo Est, Seriate, Bergamo, Italy

2 Department of Pathology, Bolognini Hospital, ASST Bergamo Est, Seriate, Bergamo, Italy

3 Department of Obstetrics and Gynaecology, Locatelli Hospital, ASST Bergamo est, Piario, Bergamo, Italy

Received April 2022; Revised and accepted July 2022

Abstract

Objective: Primary malignant urethral melanoma is a rare condition, concerning less than 1% of melanomas and 4% of all urethral cancers. The early treatment of urethral melanoma is extremely important due to the tendency to early metastasis.

Case report: 88-year-old Caucasian lady presented vaginal bleeding. At first Gynaecological examination an urethral caruncle with otherwise normal trans-vaginal ultrasound was diagnosed. The patient not reassured asked for a second consultation opting to remove the reddish fleshy polypoid lesion protruding from the urethra. Histology revealed a urethral amelanotic melanoma. The patient underwent an excision of the urethral lesion. Urologist, oncologist and gynaecologist at tumor board meeting, considering patient's age and negative PET, decided for conservative management with close clinical and imaging follow-up. 7 months after, vaginal bleeding recurred and a nodule on the anterior vaginal wall was detected and biopsied and resulted a pigmented melanoma. The patient underwent a wide margin excision. At 10 months follow-up there were no evidence of recurrence nor distant metastasis. She started a prophylactic immunotherapy with Nivolumab; at her third administration she presented only asthenia as side effect.

Conclusion: It is important to keep in mind the urethral amelanotic melanoma to allow an early removal or biopsy, preventing diagnostic delay/misdiagnosis and aiding either in better patient management or outcome.

Keywords: Amelanotic Melanoma; Urethral Caruncle; Conservative Management

Introduction

Primary malignant urethral melanoma is a rare condition, concerning less than 1% of melanomas and 4% of all urethral cancers (1- 6), being more frequent

in Caucasian female in the fifth decades (2,3).

We report this case to be aware of melanoma in case of urethral caruncle despite of its pigmentation or not. As the diagnosis is histological, it becomes mandatory to perform a biopsy preferably a local excision even if the patient is asymptomatic, also because a misdiagnosis or a delayed diagnosis carries a

Correspondence:

Dr. Paola Algeri

Email: dottoressa.algeri.p@gmail.com



Copyright © 2022 Tehran University of Medical Sciences. Published by Tehran University of Medical Sciences.

This work is licensed under a Creative Commons Attribution-NonCommercial 4.0 International license (<https://creativecommons.org/licenses/by-nc/4.0/>).

Noncommercial uses of the work are permitted, provided the original work is properly cited.

very poor prognosis. And in fact, the early treatment of urethral melanoma is extremely important due to the tendency to early metastasis (1,3). Considering our case, although there was a prompt diagnosis and treatment, there was a recurrence in a short period representing the aggressiveness of the entity.

Case report

An 88-year-old Caucasian lady came to our outpatient department for vaginal bleeding without urinary symptoms. Her medical history included chronic hypertension and atrial fibrillation both on medication. Gynaecological examination revealed a urethral caruncle with otherwise normal trans-vaginal ultrasound, so the proposal at that time was a watchful waiting approach. The patient not reassured asked for a second consultation opting to remove the reddish fleshy polypoid 3 cm-wide lesion protruding from the urethra (Figure1A). Histology revealed a

neoplasm represented by poorly cohesive epithelioid cells with large round to oval nuclei, finely granular chromatin, conspicuous nucleoli, scant eosinophilic cytoplasm and numerous mitotic figures (Figure 1B,C). Immunohistochemistry categorization of tumor cells demonstrated positivity for HMB-45 (Figure1D), S-100, Melan A, SOX-10 and p16. Furthermore, they were negative for cytokeratins AE1-AE3, CD45 (LCA) and CD79a. Fontana-Masson staining did not reveal any melanin pigment. Then and based on the histological findings was confirmed the unexpected diagnosis of urethral amelanotic melanoma.

A PET performed one month after local excision highlighted vaginal and urethral 18F-FDG increased uptake (Figure1E). While cystoscopy described a normal bladder with a millimetric formation at the urethral meatus. At that point, patient underwent an enlarged margin excision.

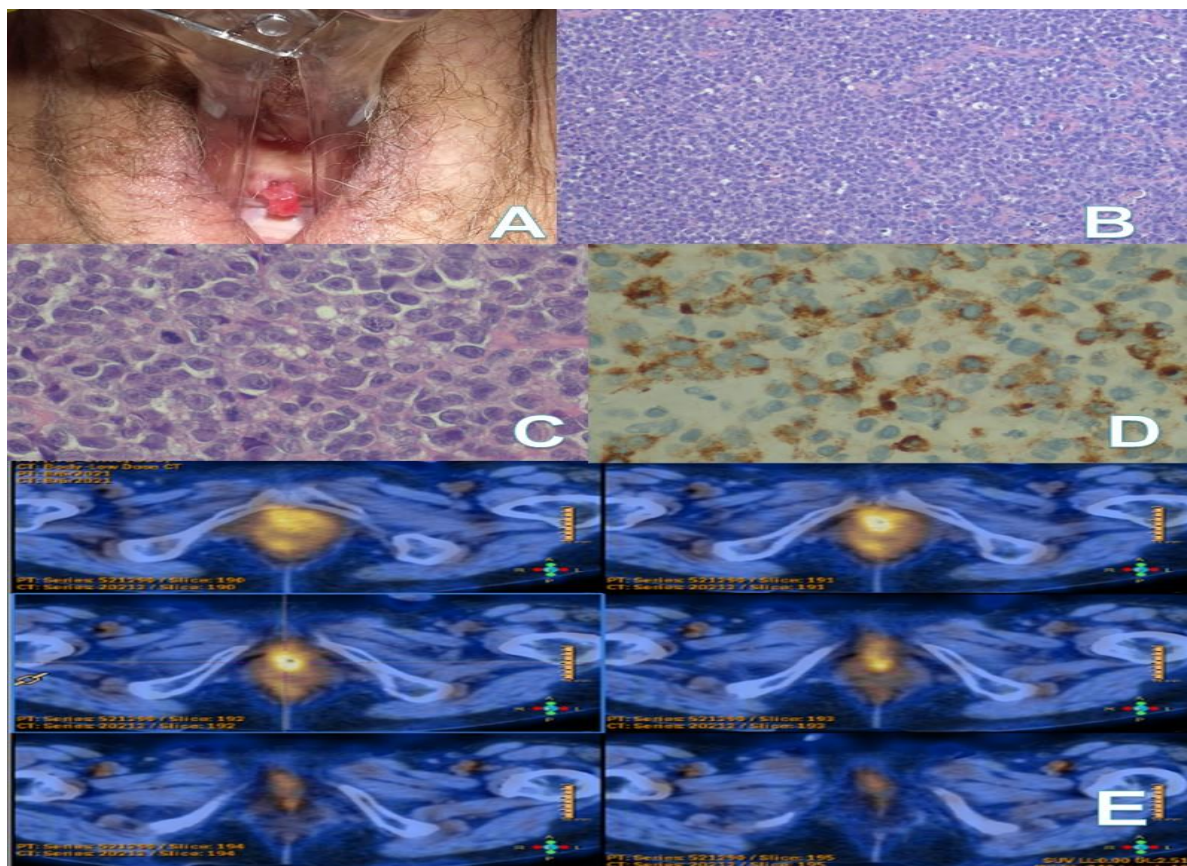


Figure 1: A. Clinical image of urethral lesion at presentation. B. Microscopic examination revealed a diffuse proliferation of round blue cells. Haematoxylin-Eosin (H&E), x200. C. In detail large epithelioid-shaped neoplastic cells with high nucleocytoplasmic ratio, prominent nucleoli, small amount of pinkish cytoplasm and frequent mitotic features. (H&E), x400: D. HMB-45 expression in tumor cells confirming that it was a melanoma. E. PET image pointing out a greater uptake of 18F-FDG in urethra and vagina.

The histological examination confirmed again a urethral amelanotic melanoma without BRAF mutation. The subsequent PET two months later was unremarkable. On that wise, urologist, oncologist and gynaecologist at tumor board meeting, considering patient's age and last negative PET, decided for conservative management with close clinical and imaging follow-up. Further workup comprehending a CT scan performed 7 months after primary diagnosis was irrelevant but vaginal bleeding recurred. On *per speculum* examination, there was a nodule on the anterior vaginal wall with hyperpigmentation on the right side. Both lesions were biopsied and they histologically corresponded to a pigmented melanoma with a morphophenotype superimposable to the first lesion. The patient underwent a wide margin excision doing fine at 10 months follow-up with no evidence of recurrence nor distant metastasis. She started a prophylactic immunotherapy with Nivolumab; at her third administration she presented only asthenia as side effect.

Discussion

To our knowledge, primary malignant urethral melanoma is a rare condition, concerning less than 1% of melanomas and 4% of all urethral cancers (1-6), being more frequent in Caucasian female in the fifth decades (2,3). Clinical presentation can include vaginal bleeding, palpable urethral mass, haematuria, dysuria and obstructive voiding symptoms (3). Additionally one-fifth are amelanotic. So in case of postmenopausal woman presenting a soft pink or red polypoid nodule at the urethral meatus, physicians would have to recognise and take into consideration in the differential diagnosis not only the possibility of caruncle, polyp or mucosal prolapse but also other pathologies of the urethra like melanoma (1, 3).

Some treatment modalities include urethrectomy with bilateral inguinal lymph node dissection or pelvic exenteration and radiotherapy (3), but the gold standard treatment is the wide surgical excision of the tumour or urethrectomy/vulvectomy. Subsequently, chemotherapy or beta-interferon can be administrated to prevent the systemic extent of the disease, and there are also new potential immunotherapies like Dabrafenib, trametinib, ipilimumab and fotemustine (4,5).

Although all treatment efforts are driven to contain the neoplasm, there is still a high local recurrence rate of about 70% (3) and obviously, lymph node metastasis is correlated with poor prognosis (7), being

advisable a check on nodal status.

Conclusion

In conclusion, urethral amelanotic melanoma like in our case can represent a tricky diagnosis and for this reason would have be kept in mind to allow an early removal or biopsy, preventing diagnostic delay/misdiagnosis and aiding either in better patient management or outcome. Again, histology will reach the diagnosis, and although the treatment is not standardized, a multidisciplinary team, considering patient's clinical conditions and desire, must personalize the decision.

Acknowledgments

The authors reported no conflict of interest.

References

1. El-Safadi S, Estel R, Mayser P, Muenstedt K. Primary malignant melanoma of the urethra: a systematic analysis of the current literature. Arch Gynecol Obstet. 2014 May;289(5):935-43.
2. Safadi A, Schwalb S, Ben-Shachar I, Katz R. Primary malignant urethral melanoma resembling a urethral caruncle. Urol Case Rep. 2017 Sep 9;15:28-29.
3. Papeš, D., Altarac, S. Melanoma of the female urethra. Med Oncol 2013;30(1):329.
4. Di Giacomo AM, Ascierto PA, Pilla L, Santinami M, Ferrucci PF, Giannarelli D, et al. Ipilimumab and fotemustine in patients with advanced melanoma (NIBIT-M1): an open-label, single-arm phase 2 trial. Lancet Oncol. 2012 Sep;13(9):879-86.
5. Flaherty KT, Infante JR, Daud A, Gonzalez R, Kefford RF, Sosman J, et al. Combined BRAF and MEK inhibition in melanoma with BRAF V600 mutations. N Engl J Med. 2012 Nov 1;367(18):1694-703.
6. Davuluri M, Long B, Semple S, Villanueva-Siles E, Aboumohamed A. Primary Urethral Melanoma: A Case Report and Literature Review. Urology. 2019 Apr;126:1-4.
7. Mafra RS, Alberti LR, Vasconcelos BM, De Oliveira RS. Metastatic urethral melanoma: case report and review of the literature. Rev Urol. 2014;16(1):47-9.

Citation: Algeri P, Munné-Collado J, Algeri M. Urethral Caruncle Masquerading a Primary Amelanotic Melanoma, the Risk of a Poor Prognosis due to Misdiagnosis. J Family Reprod Health 2022; 16(3): 217-9.