

# Umbilical Cord Hematoma and Uterine Torsion: Rare Pregnancy Complications at Tu Du Hospital in Vietnam and Review of Literature

Anh Dinh Bao Vuong; M.D., Phuc Nhon Nguyen; M.D.

Department of High-risk Pregnancy, Tu Du Hospital, Ho Chi Minh City, Vietnam

Received February 2022; Revised and accepted July 2022

## Abstract

**Objective:** Umbilical cord hematoma and uterine torsion are extremely rare complications in pregnancy. However, these should not be neglected in clinical practice in condition of abnormal fetal heart monitoring without others suspects. We hereby report rare case of umbilical cord hematoma and uterine torsion as well as review the literature. Through this report, we aim to mention on an available tool to investigate spontaneous umbilical cord hematoma on fetal well-being in such a case.

**Case report:** A women aged 35 years old (G1P0) admitted to our hospital for term gestation with uncomplicated pregnancy, except large uterine fibroid accompanied with cervical pessary. Then, an uncommon complication of umbilical cord hematoma was revealed accidentally upon cesarean section. Particularly, this dramatic event was happened along with an asymptomatic uterine torsion noticed at the same time. Preoperative diagnosis of two rare complications was missed, hence, we extracted timely baby based on another modality of management, computerized cardiotocography.

**Conclusion:** Umbilical cord hematoma along with uterine torsion is difficult to diagnosis due to its rarity. Moreover, no available tool could investigate umbilical cord hematoma prior to delivery. Surveillance on fetal heart rate monitoring may be helpful in this situation.

**Keywords:** Umbilical Cord Hematoma; Uterine Torsion; Obstetrical Complications; C-Section; Computerized Cardiotocography

## Introduction

Abnormalities of umbilical cord are very common in pregnancy. These include marginal insertion, velamentous cord insertion, umbilical cord true knot, umbilical torsion, etc. (1). Nevertheless, term umbilical cord hematoma is an extremely rare complication; almost unheard. An average obstetrician may face it once in his lifetime. The rate of this accident is of

around 1/5500-1/11000 births (2).

Up to our knowledge, the first case was reported in 1981 by Ruvinsky et al (3). Until today, we found about 10 cases published in last 10 years around the world (Table 1).

Umbilical cord is the vital line between placenta and fetus, the attachment of fetoplacental circulation. Structure of normal umbilical cord includes two arteries and one vein, surrounded by Wharton' jelly, of 40-60 cm in length and mean cord thickness was 1.21 ( $\pm$  0.39) cm (4). At term, maternal blood flow through placenta is nearly 600-700 ml/min (5).

## Correspondence:

Dr. Phuc Nhon Nguyen

Email: docternhon@gmail.com



Copyright © 2022 Tehran University of Medical Sciences. Published by Tehran University of Medical Sciences.

This work is licensed under a Creative Commons Attribution-NonCommercial 4.0 International license (<https://creativecommons.org/licenses/by-nc/4.0/>). Noncommercial uses of the work are permitted, provided the original work is properly cited.

*Umbilical Cord Hematoma and Uterine Torsion*

**Table 1:** Review of features of UCH reported in last decade in the literature

Report	Gestational age and time discovered	Antenatal sign	Risk factor	Mode of intervention	Fetal outcome	Histopathological result	Structural Anomalie accompanied	Macroscopic description
Toni.G et al, 2015 (6)	At term, At birth	Loss of fetal heart lasting 90 seconds	None	VB	Apgar score of 3/1min,5min,10min, acidosis, hypothermia, Severe HIE	Disruption in the wall of the umbilical vein with discontinuity in the layers of the subintimal and internal elastic lamina. One umbilical artery presented peripheral dissection, subintimal myxoid degeneration, and widespread disruption of the elastic fibers	Amniotic band at UC insertion into the chorionic plate, markedly congested chorionic vessels with dispersed distribution.	Not given
C. Jouannelle et al, 2011 (7)	Full-term, at delivery	Decreased fetal movement and fetal heart deceleration	Congenital factor VII deficiency	CS	Apgar score of 0/1min, 3/5min, 7/10min, then, multiorgan failure on 6 <sup>th</sup> day at NICU, spontaneous intracranial haemorrhage	Not given	None	UCH at skin junction, compressed the cord, meconium stained
Scutiero. G et al, 2018 (8)	41 weeks and 3 days	None	None	VB with elective IOL by proppes	Hypotonic, no cardiac activity at birth	Highlighted edema of Wharton's jelly, circumscribed hematic infiltrates, marked venous ectasia with delamination and hematic infiltration of the venous walls, extensive haemorrhage of Wharton's jelly within the whole portion of UC. The lumen of the vein was completely occluded by coagulated hematic material.	None	Blackish-reddish material in the proximity of the placental insertion measuring approximately 3 cm. An hematoma of the cord was noted at 34 cm from the placental insertion
McAdams et al, 2016 (9)	Not informed, after birth	None	Macrosomia, 4500gram, shoulder dystocia	VB	Asymtomatic except slightly decrease of hematocrit and bleeding from UC stump		Adrenal haemorrhage	A darkish bulge of UC
Hooper K.E et al, 2016 (10)	At term, after birth	None	None	VB with IOL	None	Not given	None	Dark red discoloration and markedly increased thickness, measuring 4.5 cm in diameter at the widest part
Koukoura et al, 2016 (11)	39 weeks	Decreased fetal movement for 12 hours, repeative severe decelerations, absence variability, meconium	None	CS	Apgar score of 8/1 min, 9/5 min	The cord had 3 vessels and histological examination of the UC revealed disruption of the vein wall and hematoma involving the Wharton's jelly. The umbilical arteries were normal	None	A large cord hematoma was evident originating from the fetal insertion measuring approximately 5 cm in length

stained

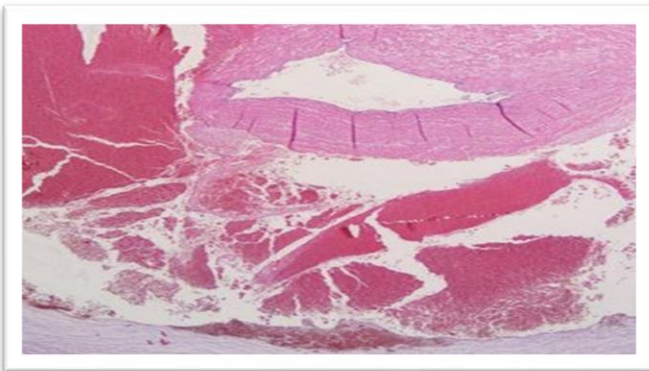
**Table 1:** Review of features of UCH reported in last decade in the literature (continue)

Report	Gestational age and time discovered	Antenatal sign	Risk factor	Mode of intervention	Fetal outcome	Histopathological result	Structural Anomalie accompanied	Macroscopic description
Koukoura et al, 2016 (11)	39 weeks at labor	None	None	Spontaneous VB	Respiratory distress soon after birth, 4 days followed at NICU	Not given	None	A huge hematoma measuring 8 cm in length was discovered closely to the fetal insertion of the cord
Arora.P.K et al, 2017 (12)	39 weeks, after birth	None	None	Spontaneous VB	Baby in good condition	Not given	None	A 4 cm long and 2 cm wide reddish purple nontender swelling was noted in the cord proximal to the level of the skin
Skowronek. R et al, 2018 (13)	41 weeks and 3 days	Bradycardia up to 80bpm	None	IOL by Foley catheter, CS	Apgar score of 1/1 min	Extravascular hematoma of UB cross-section	None	A dark-violet 15 cm section of UC near the fetus
Mota.F et al, 2019 (14)	39 weeks	None	None	VB	Follow-up without any intervention	Not given	None	Small swelling of UC stump
Khatiwada. P et al, 2021 (15)	Full-term	Two episodes of foetalheart rate tracing of the category II variety	None	IOL by Oxytocin, amniotomy, VB	Routine newborn care	Not given	The placenta had clots measuring 4x5 cm	The edematous umbilical cord was found to be stained black and red, with a size of 4x3 cm at the point of insertion into the foetalside

NICU: neonatal intensive care unit, HIE: hypoxic ischemic encephalopathy, VB: Vaginal birth, IOL: induction of labor, UC: umbilical cord

Certainly, if interruption of maternal blood supply occurs, lethal event of fetus in utero is unpreventable. Umbilical cord hematoma (UCH) is defined as incomplete extravasation of blood due to unpreventable rupture of umbilical vascular, which compress mechanically the vessels result in interrupting the blood supply for fetus and leading to acute fetal hypoxia severely. The elastic fibers and reduction in stromal myfibroblasts, which were abnormally shaped, blunted instead of stellate (6).

Regardless of pathogenesis, UCH is sequelae of the accumulation of blood into Wharton 'jelly, due to partial laceration of umbilical vein (Figure 1). In almost all cases, it occurs spontaneously without clear etiology or it may be secondary from the trauma during labor and certain diagnosis is usually determined at delivery. Meanwhile, other risk factors include anatomic abnormalities, invasive fetal procedures such as amniocentesis, oligohydroamnios, shortness of structure, traction of cord, postmaturity, chorioamnionitis, long-lasting fetal infection or in association with disorder of coagulation factors. Degeneration of umbilical cord caused by meconium stained liquor or funisitis may be a worsening factors described (16), (2), (6).



**Figure 1:** Histopathological image at the site of extravascular hematoma of cross-sectional umbilical cord (16)

Generally, diagnosis of UCH is very difficult in clinical practice because of its rarity. Almost cases were determined postnatally. Moreover, it's usually missed on sonography unless it is accompanied with abnormal Doppler flow or others structural anomalies as umbilical cord cyst, hemangioma or cord is more swelling than normal size (8), (17), (18).

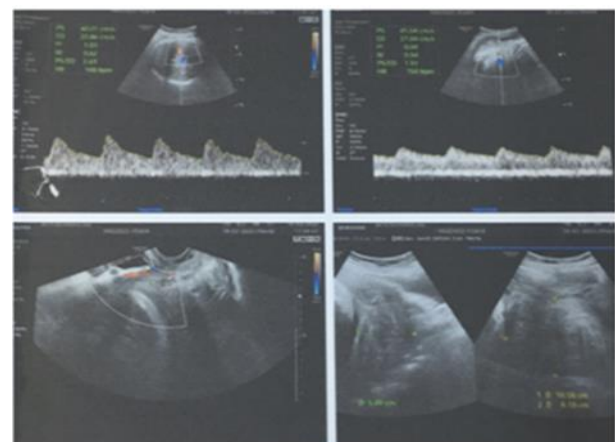
Umbilical abnormalities are strictly related to life-threatening gestational accident death. In late first and second trimesters, these abnormalities can cause

sudden and unexplained fetal death. Later, this complication is responsible for severe fetal distress and causes approximately 50% of perinatal death in this situation. Evolution is associated with hypoxic-encephalopathy, increases the rate of mortality if diagnosis is neglected. Therefore, careful examination of placenta and cord is considered in such cases (6), (19), (20).

### Case report

A 35 year old primigravida admitted to tertiary hospital due to term gestation at 39 weeks and 2 days without complaints. Her medical history recorded well-controlled hyperthyroidism by medical treatment. She is known to have a large fibroid which was accidentally discovered before pregnancy. She got pregnant after 7 years of primary infertility. Her result of GBS test (group B Streptococcus) was positive. She underwent a cervical support by pessary from 28th week for prevention of preterm risk. She has received two doses 12-mg of betamethasone for fetal lung maturity.

At hospitalization, the patient had normal vital signs without remarkable signs of labor. Digital examination showed Arabin pessary in place without cervical dilation and no uterine contraction was appeared on cardiotocography (CTG). Routine laboratory tests were within in normal limit. An ultrasound examination showed a vital foetus with an appropriate development for age and a normal Doppler flow in the middle cerebral artery as well as in the umbilical artery. Furthermore, the structure of the placenta, umbilical cord, and foetal morphology were also normal (Figure 2).



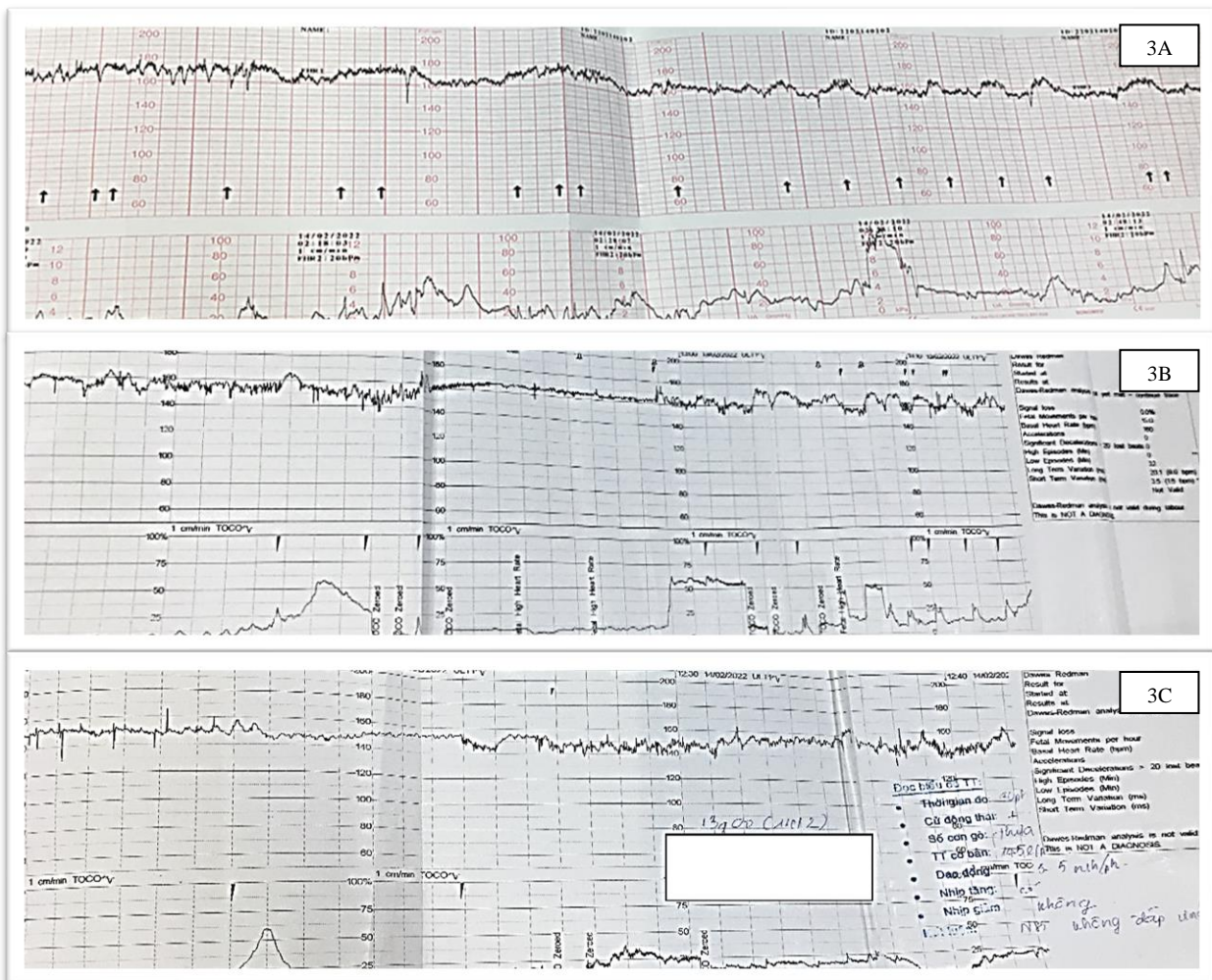
**Figure 2:** Ultrasound scan found no abnormal Doppler flow, a fibroid in dimension of 8x10 cm located at uterine isthmus.



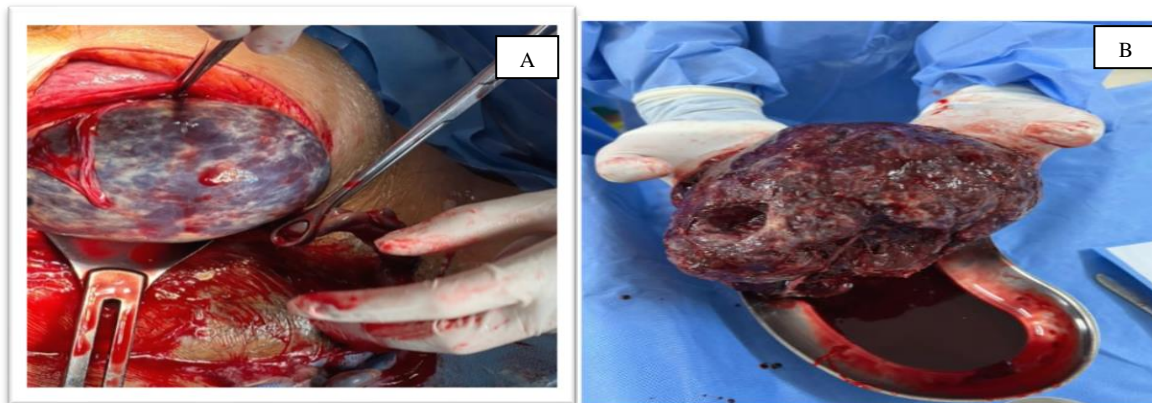
A fibroid measured about 8x10 cm in size located at posterior lower segment of uterus. However, during routine management, the fetal heart rate monitoring (FHRm) on CTG and computerized CTG was abnormal with consistent low variability and repeated light deceleration (Figure 3).

Consistently, CTG was classified by group 2 followed classification of American College of Obstetricians and Gynecologists (ACOG 2009). The lowest STV was 1.5 msec (normal value on monitor was > 3.5 msec). The foetal health was not in good condition, although the foetus was reanimated by changing the maternal lying position on the left lateral side, intravenous infusion with lactated Ringer's solution and supplemental oxygen to the mother at 6 L/min during 30 min. Therefore, we immediately

decided to perform emergency Caesarean-section (C-section) to remove baby with patient's acceptance. Interestingly, at laparotomy, uterus was rotated at 90 degree right axis, after incision of lower segmental uterus, we saved promptly a well-being male infant, weighted at 3,200 gram. The APGAR (Appearance, Pulse, Grimace, Activity, and Respiration) score of the baby was 7 and 8 at the first and fifth minutes, respectively. Fetal surface placenta was also hemorrhagic in macroscopic appearance (Figure 4). At the same time, we recognized the umbilical cord was reddish, even though amniotic fluid was normal in color. No mass was found on umbilical cord, but haemorrhage was appeared followed "flat" form along with the length from placental cord insertion to fetal cord insertion (Figure 5).



**Figure 3:** Image of CTG and computerized CTG at (A): admission, (B): surveillance, and (C): prior to C-section. Due to low variability all of them were classified as group 2 by classification ACOG 2009.



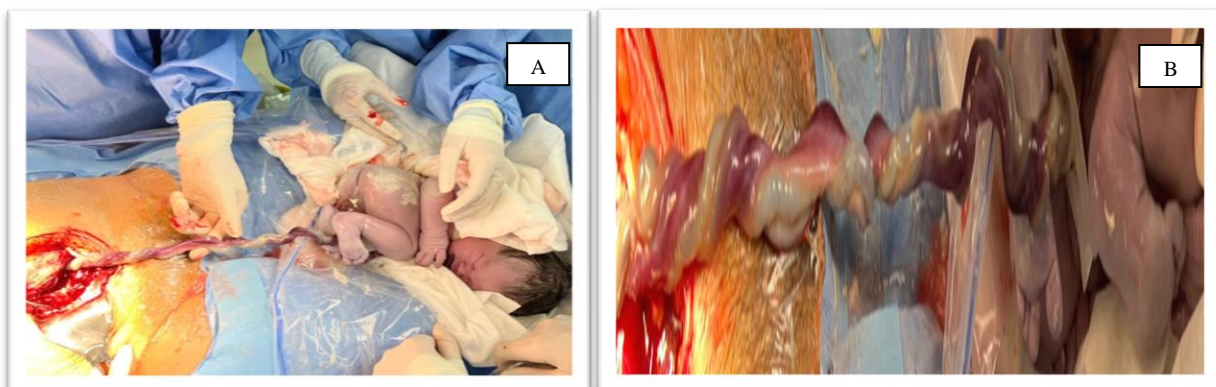
**Figure 4:** Placental image after delivery birth. A) Placenta without abruption but haemorrhage sign was observed at fetal surface, B) Placenta without detachment at maternal surface

After detorsing uterus, hemostasis of bleeding surface at placental site located was assured. In addition, we performed ligation of bilateral uterine arteries to prevent late postpartum haemorrhage due to uterine torsion. Due to large intramuscular fibroid located at posterior lower uterine segment, so we decided not promptly to carry out a myomectomy in this situation. Following all procedures, the uterus was contracted effectively. Postoperatively, the baby's umbilical cord was normally dry in 48 hours and there was no additional haematoma. Due to neonatal jaundice, the newborn baby was took blood samples for serum bilirubin as well as screening the congenital diseases routinely. Results were in normal limits. Mother and baby were discharged to home on the fifth postpartum day. The patient was scheduled 1 month later for follow-up routinely and their health conditions were still stable.

### Discussion

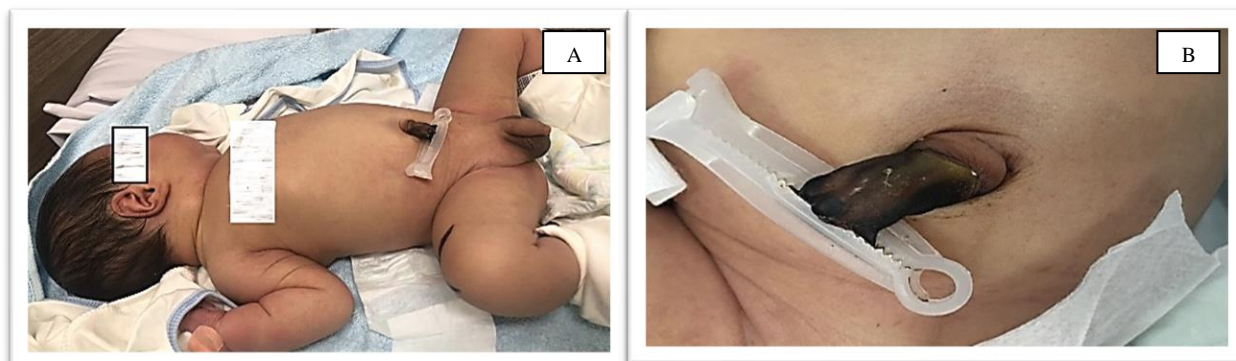
In present case, UCH was found accidentally at operation. This could be caused by uterine torsion. As haemorrhage appeared in placenta and umbilical cord although we did not find any hematoma in placenta (Figure 4). On the other hand, the patient had no suggestive symptom for clinical diagnosis of uterine torsion prior to C-section. Probably, this malposition was an acute condition so vascular damage had no enough time to develop. Moreover, uterus was not necrotic because of lack of blood supply.

Even though, necrosis is commonly mentioned as complication of gradual uterine torsion, not only in no pregnant condition but also in pregnant patient. In addition, urgent complication such as haemorrhage, disorder of coagulopathy, sepsis is also described (21).



**Figure 5:** Umbilical cord status after delivery birth. A) UCH discovered at the time of C-section, B) UCH appeared along with length of umbilical cord from placenta to fetal insertion in reddish-purple color. No abnormal mass was found





**Figure 6:** Baby condition and umbilical cord on the second day of postpartum. A) Newborn baby was in good condition on second postnatal day, B) Umbilical cord stump is more blackish than normal color after 36 hours of birth

In fact, uterine torsion is also extremely rare which lead to mortality for both mother and fetus. Some articles related to this condition diagnosed in 2<sup>nd</sup> or 3<sup>rd</sup> trimester, even at term gestation similar to the present case (22). This fatal condition had typically acute symptoms such as vomiting, vaginal bleeding, excruciating abdominal pain, even uterine necrosis due to irreducible torsion, rarely, it may be appeared without signs of alert (22). Rotation ranges between 45 degrees and 720 degrees compared with its longitudinal axis (23). Interestingly, rotation along with horizontal axis or transversal axis is also reported. Risk factors of malposition include: morphologic anomalies, pelvic tumor, pelvic adhesion, asymmetry in the transverse diameter of the uterus because of transverse presentation, lateral fibroids, bicornuate uterus, multiple pregnancies (24). In our case, the patient had no abnormality of anatomic structure which caused axial torsion except fibroid with enlarge size of around 8x10 cm. Some reports revealed that huge fibroma could attribute to uterine torsion because of asymmetric weight distribution, commonly, in non-gravid uterus and in postmenopausal periods due to atrophy of uterus. Diagnosis by imaging technology as magnetic resonance imaging (MRI) can be helpful in this complication (21), (25), (26). Until now, we have not found any case report related to uterine torsion in combination with cervical pessary. Therefore, we could not conclude cervical pessary as a risk factor with uterine fibroid in our case. We were waiting for further investigations about this mechanism.

Similar to all cases reported, no clinical sign or image scan contributed to detect antepartum UCH. However, reduced fetal movements were reported in most cases (8). In this case, we discovered

incidentally this intraoperative complication due to other indication. Precisely, we performed C-section followed abnormal fetal heart rate monitoring (FHRm) (Figure 3). Accordingly, STV was in associated with hypoxia and increased acidemia in umbilical cord blood sampling described by several authors (27), (28). The cut-off point of SVT is still unclear but some reports are agreed with low STV in accordance with poor prognostic of fetus and needed further investigation (28). Fortunately, in the present case, we assured promptly FHRm, thus, we can interfere rapidly this complication and saved baby's life. In our case, UCH was appeared following feature of haemorrhage "flat" and mass was not palpated on umbilical cord. According to literature as above-mentioned table, UCH located at proximal portion of fetal cord insertion and caused severely obstruction of blood flow (Table 1). In 2009, Tower CV *et al* and A. Barbati *et al* also report the similar case discovered spontaneously by fetal heart monitor in USA and in Italy (29), (30). Recently, Koukoura *et al.* and Khatiwada P *et al.* also reported 3 cases related to this event with the precious experience on continuous FHRm in surveillance of labor (11), (15).

In the present case, UCH was diagnosed following caesarean operation as above macroscopic description (Figure 5). Unfortunately, we did not have histopathological result compared to some reports as well as legal evidence in situation of fetal death (6), (13). Successfully, newborn's health was in good condition after birth, neonatal course was uneventful. None of anomalies was observed on examination (Figure 6).

## Conclusion

UCH is an extremely rare entity in obstetric practice.

Particularly, UCH in context of uterine torsion is an unheard phenomenon in the literature. In reality, antenatal diagnosis of two rare complications is commonly unrecognized, fetal prognosis is poor if urgent extraction of fetus is delayed. Until today, none of tool can approach in determination of this consequence. However, the accident of UCH should be considered to rule out in case of unexplained hypoxia. Following fetal heart monitoring, especially, managed by computerized CTG was strictly useful for a timely interpretation. Further data is required to elucidate this tissue.

### **Conflict of Interests**

The authors have declared no conflicts of interest.

### **Acknowledgments**

We thank the patient, who agreed to allow us to publish the clinical data. The authors are also grateful for all colleagues working at Department of High-risk Pregnancy. All of them attributed to provide us the pictures, take care for this patient and perform the operation.

### **References**

1. Bohilțea RE, Dima V, Ducu I, Iordache AM, Mihai BM, Munteanu O, et al. Clinically Relevant Prenatal Ultrasound Diagnosis of Umbilical Cord Pathology. *Diagnostics(Basel)* 2022; 12: 236.
2. Sizun J, Soupre D, Broussine L, Giroux JD, Piriou P, Ventrillon E, et al. (Spontaneous umbilical cord hematoma, a rare cause of acute fetal distress). *Arch Pediatr* 1995; 2: 1182-3.
3. Benirschke K, Kaufmann P, Baergen R. *Anatomy and Pathology of the Umbilical Cord. Pathology of the Human Placenta . Springer , Fifth Edition , New York, USA 2006.*
4. Basta M, Lipsett BJ. *Anatomy, Abdomen and Pelvis, Umbilical Cord.* 2021 Jul 31. In: StatPearls (Internet). Treasure Island (FL): StatPearls Publishing; 2022.
5. Wang Y, Zhao S. *Vascular Biology of the Placenta.* San Rafael (CA): Morgan & Claypool Life Sciences; 2010.
6. Tonni G, Bonasoni MP, De Felice C, Rossi A, Tonni S. Histopathological Findings in Spontaneous Hematoma of the Umbilical Cord: Severe Hypoxic-Ischemic Encephalopathy in a Term Survived Newborn. *Am J Forensic Med Pathol* 2015; 36: 254-6.
7. Jouannelle C, Giansily-Blaizot M, Monpoux F, Casagrande F, Poirée M, Bérard E. Spontaneous umbilical cord haematoma and congenital factor VII deficiency. *Haemophilia* 2012; 18: e24-5.
8. Scutiero G, Giulia B, Iannone P, Nappi L, Morano D, Greco P. Umbilical Cord Hematoma: A Case Report and Review of the Literature. *Obstet Gynecol Int* 2018; 2018: 2610980.
9. McAdams RM, Chabra S. Umbilical cord haematoma and adrenal haemorrhage in a macrosomic neonate with anaemia. *BMJ Case Rep* 2016; 2016: bcr2015214140.
10. Hooper KE, Sebire P. Spontaneous umbilical cord haematoma. *Archives of Disease in Childhood - Fetal and Neonatal Edition* 2016; 101: F332.
11. Koukoura O, Sveronis G, Alevra Z, Gaitana K, Kalaitzi AN, Dafoulis N, et al. Spontaneous cord hematoma: report of two cases. *J Case Reports in Perinatal Medicine* 2016; 5: 97-9.
12. Arora PK, Mohandas S, McAndrew S, Karody V. Spontaneous Umbilical Cord Hematoma. *The J Pediatr* 2017; 184: 233-233.e1.
13. Skowronek R, Zamłyński M, Kajor M, Zamłyński J, Chowaniec M. Spontaneous umbilical cord hematoma as a clinical and forensic medical problem in case of suspected obstetrician's medical malpractice. *Ginekologia Polska* 2018; 89: 642-3.
14. Mota F, Oliveira N, Fonseca M, Mimoso G. Spontaneous umbilical cord haematoma. *BMJ Case Rep* 2019; 12(6):e229952.
15. Khatiwada P, Alsabri M, Wiredu S, Kusum V, Kiran V. Spontaneous Umbilical Cord Hematoma. *Cureus*. 2021 Feb 1;13(2):e13048.
16. Mantakas X, Dalivigkas I, Aravantinos L, Goutas N, Goudeli C, Vlahos N. Placenta and Umbilical Cord Cause in Antepartum Deaths. *Cureus* 2018; 10: e3556.
17. Sepulveda W, Wong AE, Gonzalez R, Vasquez P, Gutierrez J. Fetal death due to umbilical cord hematoma: a rare complication of umbilical cord cyst. *J Matern Fetal Neonatal Med* 2005; 18: 387-90.
18. Brown R, Nicolaides K. Umbilical cord hematoma associated with an umbilical cord cyst and fetal death at 28 weeks of gestation. *J Ultrasound Med* 2000; 19: 223-5.
19. Antolin E, Castelo-branco C, Lopez A, Martinez JM, Torné A. Umbilical cord torsion; a rare cause of intra-uterine fetal death. *Journal of Obstetrics and Gynaecology* 1994; 14: 324-5.
20. Gualandri G, Rivasi F, Santunione AL, Silingardi E. Spontaneous umbilical cord hematoma: an unusual cause of fetal mortality: a report of 3 cases and review of the literature. *Am J Forensic Med Pathol* 2008; 29: 185-90.
21. Chua KJ, Patel R, Eana A, Varughese J. Uterine torsion



- with necrosis of bilateral adnexa in a postmenopausal woman. *BMJ Case Rep.* 2019; 12(6): e229311.
22. Rood K, Markham KB. Torsion of a Term Gravid Uterus: A Possible Cause of Intrauterine Growth Restriction and Abnormal Umbilical Artery Doppler Findings. *J Ultrasound Med* 2014; 33: 1873-5.
  23. Kilicci C, Sanverdi I, Bostanci E, Abide CY, Eser SK. Uterine torsion of 720 degrees in the third trimester of pregnancy and accompanying bladder torsion: a case report. *Pan Afr Med J* 2018; 29: 175.
  24. Liang R, Gandhi J, Rahmani B, Khan SA. Uterine torsion: A review with critical considerations for the obstetrician and gynecologist. *Translational Research in Anatomy* 2020; 21: 100084.
  25. Ferrari F, Ferrari FA, Negri B, Forte S, Franceschetti L, Sartori E, et al. Uterine torsion and intrauterine growth restriction: Case report and systematic literature review. *J Obstet Gynaecol Res* 2021; 47: 4224-31.
  26. Kocher M, Hirsig L. A case of uterine incarceration with unrecognized uterine torsion. *Radiol Case Rep* 2020; 15(10): 1943-7.
  27. Serra V, Moulden M, Bellver J, Redman CW. The value of the short-term fetal heart rate variation for timing the delivery of growth-retarded fetuses. *BJOG* 2008; 115: 1101-7.
  28. Wretler S, Holzmann M, Graner S, Lindqvist P, Falck S, Nordström L. Fetal heart rate monitoring of short term variation (STV): a methodological observational study. *BMC Pregnancy Childbirth* 2016; 16: 55.
  29. Towers CV, Juratsch CE, Garite TJ. The fetal heart monitor tracing in pregnancies complicated by a spontaneous umbilical cord hematoma. *Journal of Perinatology.* 2009;29(7):517-20.
  30. Barbati A, Cacace MG, Fratini D, Ceccarelli T, Capanna F, Di Renzo GC. Umbilical cord haematoma with altered fetal heart rate. *Journal of Obstetrics and Gynaecology.* 2009;29(2):150-1.

**Citation:** Vuong ADB, Nguyen PN. **Umbilical Cord Hematoma and Uterine Torsion: Rare Pregnancy Complications at Tu Du Hospital and Review of Literature.** *J Family Reprod Health* 2022; 16(3): 220-8.