

## An Unusual Case of Genital Lesion: A Vulvar Syringoma

Paola Algeri; M.D.<sup>1</sup>, Rosita Rodella; M.D.<sup>2</sup>, Cinzia Manfredini; M.D.<sup>2</sup>, Maurizio Algeri; M.D.<sup>3</sup>

1 Department of Obstetrics and Gynaecology, Bolognini Hospital, ASST Bergamo est, Seriate, Bergamo, Italy

2 Department of Pathological Anatomy, Bolognini Hospital, ASST Bergamo est, Seriate, Bergamo, Italy

3 Department of Obstetrics and Gynaecology, Locatelli Hospital, ASST Bergamo est, Piario, Bergamo, Italy

Received November 2020; Revised and accepted January 2021

### Abstract

**Objective:** Syringoma is a benign adnexal neoplasm of sweat gland, usually presenting as extra-genital lesions, while vulvar localization is rare. Moreover, syringoma is an uncommon vulvar neoplasms.

**Case report:** A 44-year-old woman with previous diagnosis of duodenal gastrointestinal stromal tumour, underwent a local surgical excision for an isolated, painful, vulvar lesion. The specimen was submitted for histological examination.

A vulvar syringoma was diagnosed.

**Conclusion:** We describe this case according on its rarity and atypical presentation as well; therefore, vulvar neoplasms encompass many differential diagnoses, among which the incidence rate of syringoma is very low. Although its rarity, syringoma should be included among the differential diagnosis for vulvar neoplasm.

**Keywords:** Vulvar Neoplasms; Syringoma; Vulvar Diseases

### Introduction

Syringoma is a benign neoplasm originating from sweat gland (eccrine) ducts. It is most common in women, after puberty (1). This tumour usually has a bilateral symmetrical distribution. The periorbital area (the lower eyelid) is the most common anatomic site. Others typical sites involved are scalp, forehead, neck, anterior chest, axillae, upper abdomen, and extremities (2-6).

Vulvar region is considered as a rare localization of syringoma. This site was described at the first time

as Lymphangioma Tuberosum Multiplex in 1872 by Kaposi and Biesiadeki (7, 8); subsequently reported in 1892 by Hartung (9) and then, in 1971 by Carneiro (1). Moreover, vulvar syringoma is usually associated to other localizations (10, 11).

Frequently, this lesion is asymptomatic; nevertheless, rarely, vulvar pruritus or pain could occur, mainly during menstrual period or in case of pregnancy; in addition, a size increase is reported, too (11-13). On the basis of this, a hormone responsiveness has been investigated and the expression of Estrogen and Progesterone receptor has been established with immunohistochemistry (14-17).

Three kinds of clinical manifestations have been documented: 1) multiple flesh-coloured or

### Correspondence:

Dr. Paola Algeri

Email: [dottoressa.algeri.p@gmail.com](mailto:dottoressa.algeri.p@gmail.com)

Copyright © 2021 Tehran University of Medical Sciences. Published by Tehran University of Medical Sciences.



This work is licensed under a Creative Commons Attribution-Noncommercial 4.0 International license (<https://creativecommons.org/licenses/by-nc/4.0/>). Noncommercial uses of the work are permitted, provided the original work is properly cited.

brownish papules with symmetrical involvement of the labia majora, 2) cystic lesions or 3) lichenoid plaques (11, 12, 18, 19).

Accordingly, vulvar syringomas is a special diagnostic challenge due to all possible differential diagnosis in case of multicentre papular lesions of the vulva, vulvar pain and vulvar pruritus. Therefore, histological examination is necessary to determine the disease: a skin incisional biopsy is enough to confirm the diagnosis (11).

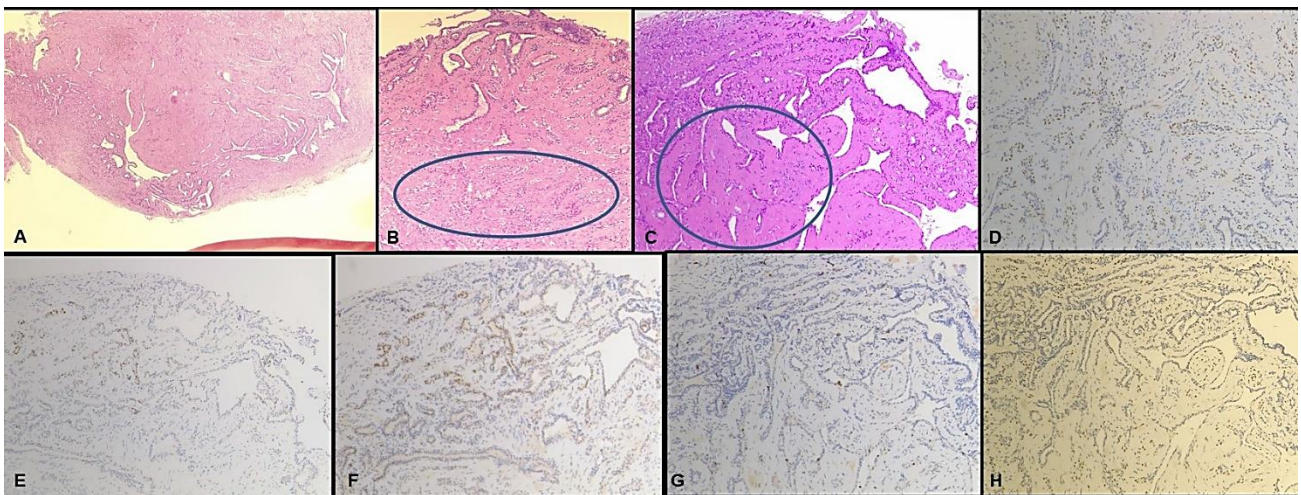
Histology shows normal epidermis, while the examination of dermis and mid dermis reveals a plethora of small colloid cystic ducts containing colloid material and solid epithelial strands within the surrounding fibrous stroma. Two rows of flat epithelial cells with clear cytoplasm line the walls of these ducts, although cuboidal cells may sometimes be found lining the lumen as well. At the end of the ducts are often found comma shaped "tadpole" tails comprised of bulging formed by weakly organized ductal structures (13, 20, 21).

We decided to report this unexpected case in relation to the rarity of vulvar site and the peculiarity of its presentation. We believe that sharing can be helpful in other similar cases.

### Case report

A 44 years old Caucasian patient was admitted to our

gynaecological department for the evaluation of a solid vulvar lesion, with variable size between 3 to 10 millimetres, localized at left minor labium, which appeared 18 months earlier. There was no family history of similar lesions. Five months before a diagnosis of duodenal gastrointestinal stromal tumour had been made and the patient was treated with Imatinib 400 mg/daily. With the beginning of immunotherapy, the vulvar lesion became painful, while before it always had been asymptomatic. Since the lesion become painful and considering its persistence without regression, an excisional biopsy was performed under local anaesthesia. Three fragments (the greater of 0.4 cm) were submitted to the pathologist. The diagnosis was not straightforward due to ischemic changes with scattered hemosiderin-laden macrophages and coexisting chronic inflammation. The lesion was dermal-based showing epithelial cells arranged in tubules or trabeculae with comma shaped extensions. These ducts were lined by myoepithelial elements with clear cell appearance. The stromal element was fibro-hyaline. Not infiltrative borders, no atypia, no mitotic figures, no local destruction were observed. Though immunohistochemistry was not required for diagnosis, nonetheless, the specimen was investigated for p63 expression to highlight myoepithelium and Mib1/Ki67 revealing a very low proliferative index (Figure 1).



**Figure 1:** Histological features of vulvar syringoma (10x). A. A proliferation of benign small ducts lined by an inner layer of cuboidal epithelial cells with an outer border of myoepithelial elements with clear cell appearance. B. Superimposed ischemic changes (surrounded by a blue circle in the figure) partially obscuring the neoplasm structure. C. Biphasic component with hyalinized stroma (surrounded by a blue circle in the figure) is shown. All the subsequent figures showed Immunohistochemistry, which coloured in brown specifically: D. p63 immunostaining to highlight myoepithelium. E. Small duct epithelial cells expressing receptors for Estrogen. F. Small duct epithelial cells expressing receptors for Progesterone. G. A very low proliferation index immuno-stained with Mib1/Ki67.

A vulvar syringoma was diagnosed. A subsequent clinical evaluation of the patient excluded other syringomas interesting different sites of the body. The follow up was regular: specifically, the gynaecological and dermatological evaluations one and three months after surgery were both normal.

## Discussion

The management of vulvar lesions requires to assess various differential diagnosis, both benign and malignant: this could represent a diagnostic challenge for gynaecologist and dermatologist as well (1, 10, 22-24). Specifically, the differential diagnosis should include epidermal cyst, steatocystoma multiplex, lymphangioma circumscriptum, lichen simplex chronicus, Fox-Fordyce angiokeratomas disease, senile angioma, condyloma acuminatum, candidiasis, scabies, pediculosis, allergic/irritant contact dermatitis, psoriasis and lichen (1, 10, 14, 22-24).

When the diagnosis of syringoma is confirmed by histology, the treatment usually is not mandatory considering its benign nature, while it is recommended in case of symptoms or cosmetic concern. Syringomas must be removed surgically, due to a low response to medical therapy, however, recurrence is frequent (6).

We considered to share the experience with this case of vulvar syringoma according to the rarity of vulvar localization (7-11) and its atypical presentation (11-13).

In particular, the uniqueness of our case lies in the presence of an isolated solid lesion instead of multiple symmetrical lesions which are typical in vulvar syringomas. Furthermore, the lack of association with syringomas in other body sites (10, 11) is unusual too. Finally, vulvar syringoma is usually painless.

Therefore, we think it is correct to include vulvar syringoma among the diagnostic panel for vulvar neoplasm regardless clinical presentation.

The onset of pain after immunotherapy needs further investigations to evaluate possible relationship between hormone responsiveness and the treatment with Imatinib in vulvar syringoma. In fact, even if the expression of hormone receptor was described (14-17), no information was reported in literature, as best of our knowledge, about the association between syringoma and immunotherapy.

## Conclusion

In case of vulvar lesions, the possibility of a vulvar syringoma should raise a point of concern when

evaluating all possible differential diagnosis, even though the clinical presentation is atypical. A biopsy is mandatory for the purpose of a proper diagnosis.

## Acknowledgments

Authors have no conflict of interests.

## References

1. Carneiro SJ, Gardner HL, Knox JM. Syringoma. Three cases with vulvar involvement. *Obstet Gynecol* 1972; 39:95-9.
2. Elder D, Elenitsas R, Ragsdale BD. Tumors of the epidermal appendages. *Lever's histopathology of the skin*. Lippincott-Raven 1997; 778-9.
3. Shelley WB, Wood MG. Occult syringomas of scalp associated with progressive hair loss. *Arch Dermatol* 1980; 116:843-4.
4. Tagami H, Inoue F, Yamada M, Egami K. Syringoma of the forehead. *Int J Dermatol* 1983; 22:113-4.
5. Van den Broek H, Lundquist CD. Syringomas of the upper extremities with onset in the sixth decade. *J Am Acad Dermatol* 1982; 6:534-6.
6. Baker GM, Selim MA, Hoang MP. Vulvar adnexal lesions: a 32-year, single institution review from Massachusetts General Hospital. *Arch Pathol Lab Med* 2013; 137:1237-46.
7. Kaposi, M. *Hebra diseases of the skin. Lymphangioma Tuberosum Multiplex*. London, the New Sydenham Society. 1874; 3:386.
8. Biesiadeki, A. *Anatomischen Tuberosum multiplex: untersuchungen aus der Pathologisch Lymphangioma Institute in Krakau*. Vienna: Wilhelm Braumuller 1972; 2.
9. Van der Putte SC. Anogenital "sweat" glands. Histology and pathology of a gland that may mimic mammary glands. *Am J Dermatopathol* 1991; 13:557-67.
10. Thomas J, Majmudar B, Gorelkin k. Syringoma localized to the vulva. *Arch Dermatol* 1979; 115:95-6.
11. Huang YH, Chuang YH, Kuo T, Yang LC, Hong HS. Vulvar syringoma: a clinicopathologic and immunohistologic study of 18 patients and results of treatment *J Am Acad Dermatol* 2003; 48:735-9.
12. Young AW, Herman EW, Tovell HM. Syringoma of the vulva: incidence, diagnosis. and cause of pruritus. *Obstet. Gynecol.* 1980; 55:515-8.
13. Carter J, Elliot P. Syringoma: an unusual cause of pruritus vulvae. *Aust N Z J Obstet Gynaecol* 1990; 30:382-3.
14. Wallace ML, Smoller BR. Progesterone receptor positivity supports hormonal control of syringomas. *J Cutan Pathol* 1995; 22:442-5.
15. Goltz RW. Syringoma (syringocystadenoma). Harper and Row; 1976, 22-24.

## Vulvar Syringoma

16. Turan, C, Ugur M, Kutluay L, Kukner S, Dabakoglu T, Aydogdu T, et. Vulvar syringoma exacerbated during pregnancy. *Eur J Obstet Gynecol Reprod Biol* 1996; 64:141-2.
17. Yorganci A, Kale A, Dunder I, Ensar A, Sertcelik A. Vulvar syringoma showing progesterone receptor positivity. *BJOG* 2000; 107:292-4.
18. Ghatt HJ, Proia AD, Tsoy EA. Malignant syringoma of the eyelid. *Ophthalmology*. 1984; 91:987-90.
19. Perez-Bustillo A, Ruiz-Gonzalez I, Delgado S, Alonso T, Ingelmo J. Vulvar syringoma: a rare cause of vulvar pruritus. *Actas Dermosifiliogr* 2008; 99:580-1.
20. Isaacson D, Turner ML. Localized vulvar syringomas. *J Am Acad Dermatol* 1979; 1:352-7.
21. Pincus SH, McKay M. Disorders of the female genitalia. *Dermatology in General Medicine*. New York: McGraw-Hill 1993, 1463-81.
22. Brown SM, Freeman RG. Syringoma limited to the vulva. *Arch. Dermatol* 1971; 104:331.
23. Belardi MG, Maglione MA, Vighi S, Di Paola GR. Syringoma of the vulva: a case report. *J Reprod Med* 1994; 39:957-9.
24. Di Lemia V, Bisighini G. Localized vulvar syringomas. *Pediatr Dermatol* 1996; 13:80-1.

**Citation:** Algeri P, Rodella R, Manfredini C, Algeri M. **An Unusual Case of Genital Lesion: A Vulvar Syringoma.** *J Fam Reprod Health* 2021; 15(1): 70-3.